"CLINICAL STUDY ON THE EFFICACY AND TOLERABILITY OF TRIAMCINOLONE ACETONIDE DELIVERED BY SKIN PATTING AND IONTOPHORESIS ON FEMALE VOLUNTEERS WITH ALOPECIA AREATA INCOGNITA AND LICHEN PLANO PILARE"

Michela Starace, Bianca Maria Piraccini
Dermatology, Department of Experimental, Diagnostic and Specialty Medicine, University of Bologna, Italy

Objective

The aim of the study was to evaluate the efficacy and tolerability of a topical drug (triamcinolone acetonide) delivered by skin patting and iontophoresis for the treatment of alopecia areata incognita and lichen plano pilare in female patients, for a period of 4 months. The evaluation was both subjective, through the judgement of the operator and the patient, and objective, through the comparison of global pictures and trichoscopy.

Materials and methods

Ten patients were enrolled over a period of one month, 5 patients were suffering from alopecia areata incognita and 5 patients were suffering from lichen plano pilare.
Volunteers aged between 20 and 72 years were included in the study.
Subjects suffering from precancerous or neoplastic conditions, or from serious systemic diseases (diabetes, cirrhosis); pregnant and lactating women were excluded from the study.
The study had a total duration of 4 months.
During the first visit, the volunteer was assessed by the researcher and was enrolled in the study according to the inclusion criteria.
During the first enrolment visit (T0), patients underwent a dermatological examination, global pictures and trichoscopy using Trichoscan® (FotoFinderdermoscope, Teachscreen Software, Bad Birnbach, Germany).
The volunteer underwent physical treatment with skin patting and iontophoresis on 4 consecutive sessions, one every 3 weeks, and she was clinically evaluated by the researcher. At the final visit 3 months later, the patient was re-evaluated with instrumental methods.
The volunteer answered a questionnaire on the effect of the treatment, the cosmetic pleasantness of the product and its effectiveness.
During each follow-up visit the patient was given local therapy by topical application of a gel containing triamcinolone acetonide and then she was treated with the skin patting device and iontophoresis to allow absorption of the product.

Results

Ten female patients, 5 suffering from alopecia areata incognita and 5 from lichen plano pilare, were enrolled in the study. All patients completed the study without adverse reactions or side effects.

Tricoscope

Trichoscopy showed improvement in all 10 patients.

ALOPECIA AREATA INCOGNITA

A considerable reduction of inflammatory signs was evidenced: yellow dots/empty follicles, short regrowing hair, pigtail hairs, vellus hairs in all patients with disappearance of these signs. In only one patient there was a reduction of the signs seen and not a total disappearance. The pull test was strongly positive at the beginning but showed after 4 months a disappearance of the hair loss.

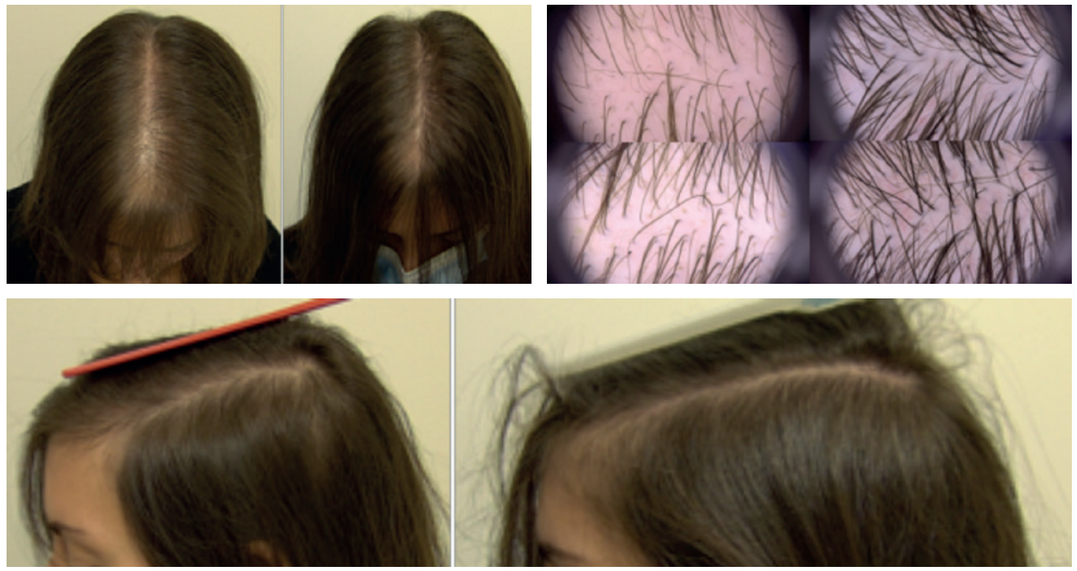

LICHEN PLANO PILARE

A significant reduction in the inflammatory signs: perifollicular hyperkeratosis, erythema and hair casts was observed in all patients with the disappearance of these signs at the end of the treatment cycle. Another important factor that was observed in all patients was an increase in diameter in the surrounding hair. Only in two patients was a reduction of the signs and not a total disappearance seen. The weakly positive pull test at the beginning was negative at the final examination after 4 months.

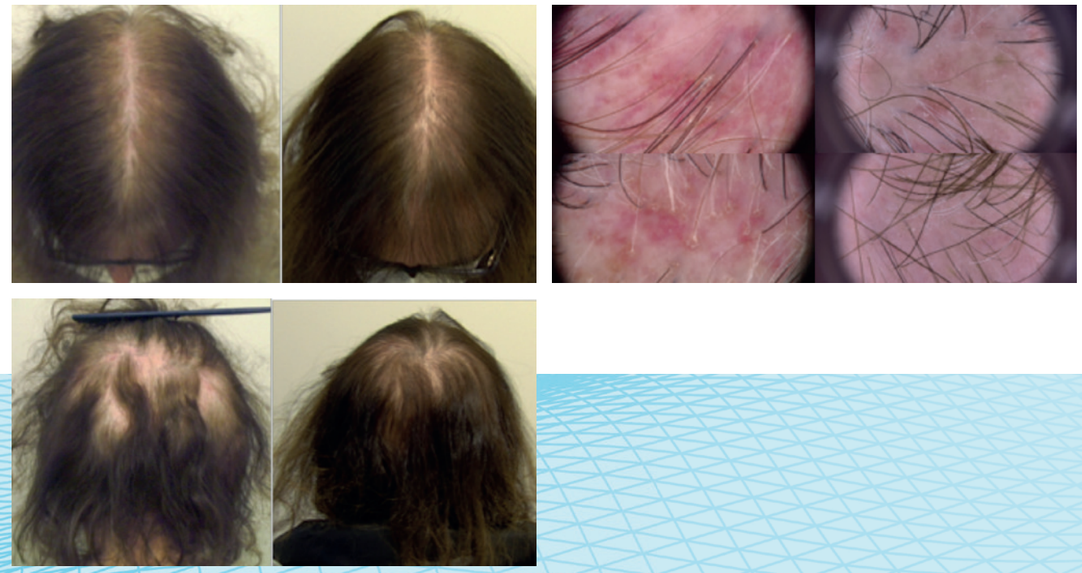

EVALUATION BY THE RESEARCHER

After 4 months, the investigator's assessment showed effectiveness in all patients:, no patient was judged to have worsened since the first visit.
After 4 months, the investigator's assessment showed excellent therapeutic efficacy in all patients: 1 with slight improvement, 1 with moderate improvement and 8 with significant improvement.

PATIENT EVALUATION

The patient evaluation showed efficacy in all patients: 3 with moderate improvement and 7 with significant improvement. In addition, all the patients with lichen plano pilare reported a significant reduction in itching after the first treatment and a disappearance after the second treatment.

SKIN PATTING STUDY ON ALOPECIA AREATA INCOGNITA

Patient	Age	Sex	Pull test	Empty follicles	Vellus hair	Hair regrowth	Pig tails hairs
1	33	F	Neg	A	A	A	A
2	57	F	Neg	A	A	A	A
3	72	F	Neg	A	A	A	A
4	49	F	Neg	A	A	R	R
5	20	F	Neg	A	A	A	A

SKIN PATTING STUDY ON LICHEN PLANO PILARIS

Patient	Age	Sex	Pull test	Perifollicular hyperkeratosis	Erythema	Hair cast	Hair in the periphery
1	61	F	Neg	A	R	A	P
2	60	F	Neg	A	A	A	P
3	54	F	Neg	A	A	A	P
4	68	F	Neg	R	R	A	P
5	68	F	Neg	R	R	A	P

Absent: A Reduced: R Present: P

Discussion and conclusion

Alopecia areata incognita is an autoimmune inflammatory hair disease presenting with an intense hair loss reported by the patients in a short time. It generally affects young females, and, on physical examination, the pull test is positive. Trichoscopy can now diagnoses the condition non-invasively, showing mainly in the parietal regions the presence of inflammatory signs: yellow dots, short hair regrowth and pigtail hairs. These signs disappear as the disease and hair loss improves.

Lichen plano pilaris is an autoimmune inflammatory disease presenting with scarring alopecia. The symptom generally reported by patients is an incoercible itching that underlines the activity of the disease. On trichoscopy, the activity of the disease is observed by the presence of perifollicular hyperkeratosis, hair casts and erythema. Also, in this case the disappearance of these signs identifies the reduction of the inflammatory phase. With a scarring evolution, the therapy is useful to block the inflammatory activity because the regrowth in the affected areas is not possible, but with the help of medical therapy it is possible to thicken the surrounding areas to better cover the affected ones.

Skin Patting® is a patented technique designed to increase hair follicle activity through 3 combined mechanisms: multiple microdermal incisions in the scalp, pressure waves and iontophoresis. The first action of the device is a controlled microdermabrasion with a sequence of micro wounds that stimulate the repair process of the dermis with increase vascularization, multiplication of fibroblasts and increase production of collagen and elastin.
The device also causes a radial pressure wave (mechanical action) directly on the scalp which produces three different effects: enhancement of blood microcirculation, stimulation of cell metabolism which facilitates the uptake of active ingredients, stimulation of fibroblast activity with increase production of collagen and elastin. Finally, iontophoresis determines a muscular stress caused by electrostimulation, creating an immediate tensor effect followed by relaxation, enhancing the skin's contractile capacity, and inducing dilation of the skin pores, which facilitates the absorption of active ingredients. At the end of the treatment, the scalp is irradiated with red LED light that emits a coherent monochromatic non-collimated light with a short wavelength variability (+ - 5%) that has a bio-stimulating effect on fibroblast and elastin production and a strong anti-inflammatory action.

Skin patting® and the delivery of topical steroid therapy through iontophoresis guarantee absorption of the active ingredient without the use of an invasive procedure, but with the same effectiveness. This combination of physical therapy of skin patting and iontophoresis combined with the deep application of steroid therapy in these inflammatory pathologies, aims to enhance the anti-inflammatory action and obtain results in a very short time, thus reducing the risk of irreversible thinning in the LPP.

Our study confirms the fundamental role of the association between skin patting® and steroid therapy delivered by the iontophoresis technique in blocking the inflammatory state of the two pathologies and allowing the regrowth of the hair affected in alopecia areata incognita or the thickening of the peripheral hair in lichen plano pilaris. This technique represents a safe and useful option for treating two inflammatory hair diseases, through mechanisms including activation of fibroblasts and elastin on the scalp in wound healing conditions, regeneration of the anagen phase of new hair by stimulation of blood microcirculation and the anti-inflammatory effect of steroid therapy.

In addition, this procedure is simple for the operator and extremely pleasant for the patient.
Our study showed a significant improvement in female patients suffering from alopecia areata incognita and lichen plano pilaris, with a reduction in inflammatory signs and hair loss in all areas of the scalp treated.